

Patient: Anonymous

Doctor: John Smith

Notation: Universal

Notes: Please evaluate area of 31 for implant placement.

Report Date: June 20, 2018

Birthday: Anonymous

Scan Date: June 18, 2018

**Areas of Interest**

- Site 31: no pathology is noted. The bone demonstrates normal cortical outlines and contours. The buccal and lingual walls are maintained. Trabecular architecture is within normal limits.

**Incidental Findings**

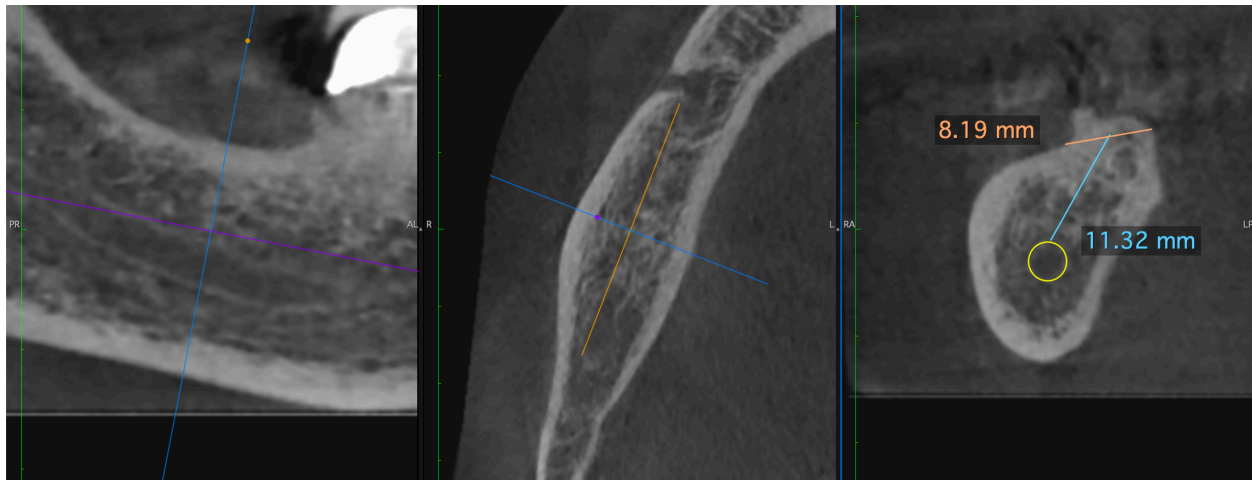
- None.

**Impressions**

- There are no pathologies noted that would prevent implant placement.

**Radiologist**

Digitally signed by Mohannad Hashem



Site 31